

# Venous Air Embolism during Anterior Lumbar Surgery

Susie J Cho, Stephen O Bader, James W Heitz

## ABSTRACT

The use of transesophageal echocardiography (TEE) has improved the detection of venous air embolism (VAE), especially in the case of small VAE where clinical changes can be subtle and erroneously attributed to volume status or cardiac function. We present a case of VAE in a 62 years old female that occurred during anterior lumbar spine surgery that was diagnosed with the aid of TEE. As anterior lumbar spines surgery is traditionally not associated with VAE, we believe this is the first reported case of VAE in this type of procedure.

**Keywords:** TEE, Air embolism, Spine surgery, Intraoperative hypotension.

**How to cite this article:** Cho SJ, Bader SO, Heitz JW. Venous Air Embolism during Anterior Lumbar Surgery. *J Perioper Echocardiogr* 2013;1(1):30-32.

**Source of support:** Nil

**Conflict of interest:** None declared

## INTRODUCTION

The entrainment of air into the venous vascular system, venous air embolism (VAE), is possible whenever the operative site is above the level of the heart or a negative pressure gradient exists between the surgical site and the central venous system.<sup>1</sup> The incidence may be as high as 80% for posterior fossa craniotomy<sup>2</sup> in the seated position and less for neurosurgical procedures in the lateral, supine and prone position with incidence decreasing to 15 to 25%.<sup>3</sup>

## CASE REPORT

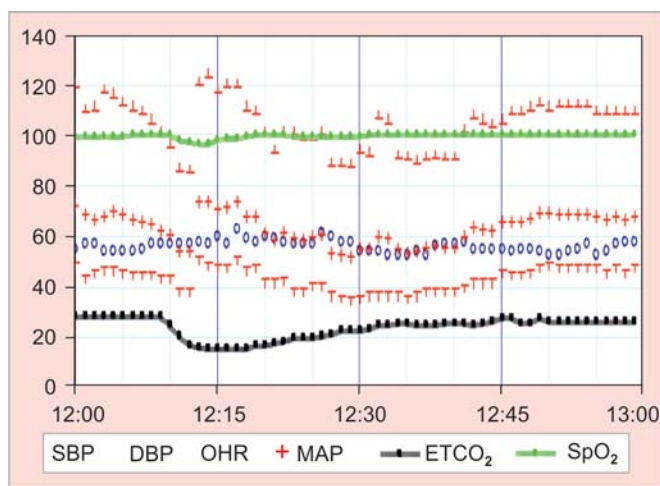
A 62-year-old woman, American Society of Anesthesiologists (ASA) Physical Status 2, with pseudoarthrosis and stenosis at L3-L4 and L5-S1 presented for combined posterior-anterior-posterior lumbar decompression and fusion with general anesthesia. Her past medical history included hypertension, hyperlipidemia, sleep apnea, diabetes mellitus type 2 and depression. Her past surgical history included L4-L5 lumbar fusion, right lung cystectomy and cholecystectomy without complications from prior anesthesia. Bispectral index, radial arterial line, electroencephalogram (EEG), somatosensory and motor evoked potentials, and standard ASA monitors were applied. Intravenous induction of general anesthesia and endotracheal intubation were routine and without difficulty. Anesthesia was maintained with 0.5 mean alveolar concentration (MAC) of isoflurane and continuous infusion of propofol with intermittent boluses of fentanyl.

Posterior lumbar decompression and fusion were completed in the prone position and without complication. The anterior portion of the procedure was performed in the supine position through a midline abdominal incision via a left-sided retroperitoneal approach that required mobilization and retraction of the left common iliac artery and aorta. During dissection through the left lateral segmental arteries and veins a laceration was made to the left iliac vein. Blood pressure decreased acutely from 112/47 to 85/40 mm Hg over a 6-minute period and was treated with 10 mg of ephedrine followed by 100 µg of phenylephrine with appropriate response. Blood pressure continued to remain lower than baseline and an additional dose of ephedrine was required 30 minutes later for a blood pressure 89/38 mm Hg. Pulse oximetry saturation (SpO<sub>2</sub>) decreased from 100 to 96% returning to 100% over a 5-minute period. End-tidal carbon dioxide (ETCO<sub>2</sub>) abruptly decreased from 29 to 16 mm Hg with gradual return to baseline over 30 minutes (Fig. 1). Breath sounds were present and clear bilaterally and chest excursion was symmetric, no cardiac murmur was appreciated. Cardiac monitoring showed sinus tachycardia at approximately 100 beats per minute (bpm). No changes were observed in the EEG or somatosensory-evoked potentials.

Arterial blood gas trended at 5, 30 and 105 minutes after incident were significant for decline in pH to 7.28, 7.25 and return to 7.31, increase in PaCO<sub>2</sub> to 48, 52 and return to 43 mm Hg, PaO<sub>2</sub> reflected adjustment in FiO<sub>2</sub> from 0.5 to 1.0 from 139 to 256, and 218 mm Hg. Ratio of alveolar dead space to tidal volume ventilation (V<sub>D</sub>/V<sub>T</sub>) increased to 0.67, 0.5 and returned to 0.3 (Table 1).

Transesophageal echocardiography (TEE) was performed approximately 15 minutes after the incident. Examination revealed no air actively entering or present in the right atrium or right ventricle, although residual microbubbles were seen in the left atrium and left ventricle (Fig. 2).

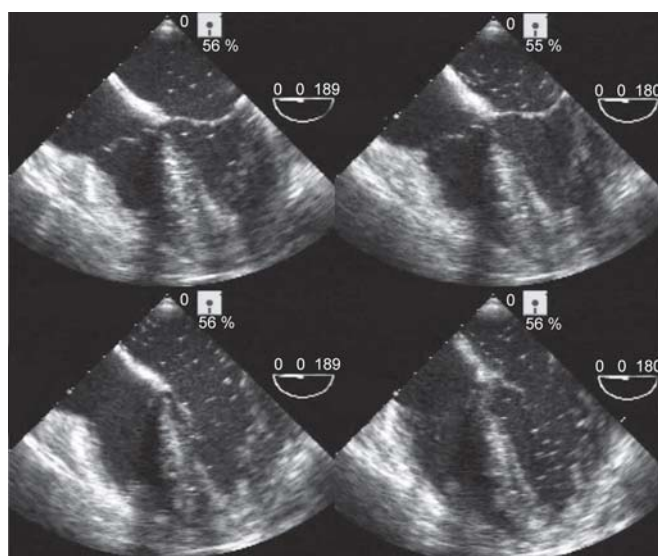
Further examination by TEE revealed no evidence of right ventricular strain, both right and left chambers displayed normal systolic and diastolic motion, and valves appeared normal in structure and motion. Agitated saline test was performed against elevated positive end expiratory pressure (PEEP) and septal wall defect was not identified. Microbubbles were again visualized in the left heart after 3 to 4 beat disappearance from right heart, suggesting a right-to-left intrapulmonary shunt.



**Fig. 1:** Anesthesia record after VAE. Time 12:08 shows abrupt decline in ETCO<sub>2</sub>, pulse oximetry saturation and blood pressure

**Table 1:** Arterial blood gas listed at times drawn in minutes before and after time zero for VAE. PaCO<sub>2</sub> and V<sub>D</sub>/V<sub>T</sub> increased after VAE. FiO<sub>2</sub> was increased from 0.5 to 1.0 between time +5 minutes and +30 minutes

Time	pH	PaCO <sub>2</sub>	PaO <sub>2</sub>	HCO <sub>3</sub>	O <sub>2</sub> Sat	FiO <sub>2</sub>	V <sub>D</sub> /V <sub>T</sub>
-105 mins	7.35	44	189	24	99	0.5	0.33
+5 mins	7.28	48	139	22	98	0.5	0.67
+30 mins	7.25	52	256	22	100	1	0.50
+105 mins	7.31	43	228	21	99	1	0.35



**Fig. 2:** TEE images after VAE. Note presence of residual microbubbles in left atrium and left ventricle

Surgical control of the laceration was obtained within a few minutes after initial onset of the acute event. The operating room table was repositioned to place the patient in slight left-side down Trendelenburg position. Depression in hemodynamic parameters continued to improve over the next 60 minutes and anterior and posterior decompression and fusion of the lumbar spine continued without further intervention.

## DISCUSSION

VAE is rare during anterior lumbar spine surgery in the supine position as it is reported more often during posterior lumbar spine surgery in the prone position.<sup>4</sup> Case reports of VAE during anterior spine surgery are limited primarily to the cervical spine in the supine position, where incidence can be as high as 10%.<sup>5</sup> A case of iliac vein air embolism was reported during open hysterectomy after laceration to the iliac vein had occurred.<sup>6</sup>

This patient experienced early signs of VAE including a decrease in PaO<sub>2</sub>, decrease in SpO<sub>2</sub>, and decrease in ETCO<sub>2</sub>. Monitors to detect appearance of end-tidal nitrogen (ETN<sub>2</sub>), increase in central venous pressure and pulmonary artery pressure are not recommended for procedures with a low risk for VAE<sup>1</sup> and consequently were not present. The patient experienced a VAE which was small to medium in size. Later signs suggestive of medium to large VAE, such as profound hypotension, ECG changes, decrease in cardiac output and cardiac dysrhythmia were not observed.

As reported by Gildenberg, hemodynamic decline appears at 0.69 ml/kg/min of air, classic mill wheel murmur is audible at 1.96 ml/kg/min of air, and potential lethality at greater than 2.0 ml/kg/min of air.<sup>7</sup> The severity of VAE is determined by both the rate and volume of air entrained.<sup>8</sup>

TEE has the highest sensitivity and detects air embolus at 0.02 ml/kg,<sup>9</sup> which is twice as sensitive as precordial Doppler, which detects at 0.05 ml/kg.<sup>10</sup> Both monitors are less specific yet more sensitive than ETN<sub>2</sub> which detects at 0.5 ml/kg.<sup>11</sup>

Clinical scenarios where early detection of VAE may prove beneficial are higher risk procedures where VAE is more likely or in patients whose clinical status is marginal where even small VAE would not be tolerated. Small air embolus in the setting of concurrent cardiac septal defect would allow direct entry of air into the cerebral circulation which would have profound clinical consequences. In addition, paradoxical air embolism is possible even when there is no fixed intracardiac defect as transpulmonary air passage can occur.<sup>12</sup>

The routine use of TEE is limited by clinical cost, the need for specialized skills, and the risk of clinical complication including oropharyngeal, esophageal or gastric injury. For procedures where VAE is deemed low probability, TEE may not need to be placed preincision but kept readily available.

Small VAE may go clinically unrecognized. Without TEE, transient hypotension with decreased ETCO<sub>2</sub> could be attributed to a primary cardiac problem or hypovolemia. TEE allows early detection and reduces the chance for delay

in diagnosis and decreases the potential for small VAE to develop into larger, catastrophic venous air embolus.

VAE is rarely reported with lumbar spine surgery in the supine position. Increased use of monitoring devices, particularly the more routine use of TEE, has allowed detection of smaller VAE that may have previously been misdiagnosed due to its mild-moderate clinical presentation. This is the first documented case of VAE during surgery of the anterior lumbar spine.

## REFERENCES

1. Mirski MA, Lele AV, Fitzsimmons L, Toung TJK. Diagnosis and treatment of vascular air embolism. *Anesthesiology* 2007;106:164-77.
2. Papadopoulou G, Kuhly P, Brock M, Rudolph KH, Link J, Eyrich K. Venous and paradoxical air embolism in the sitting position: A prospective study with transesophageal echocardiography. *Acta Neurochirurgica* 1994;126:140-43.
3. Albin MS, Carroll RG, Maroon JC. Clinical considerations concerning detection of venous air embolism. *Neurosurg* 1978;3:380-84.
4. Albin MS, Ritter M, Pruett CE, Kalff K. Venous air embolism during lumbar laminectomy in the prone position: Report of three cases. *Anesth Analg* 1991;73:346-49.
5. Wasnick JD, Vassallo SA, Hoffman WJ, Russell TK, Eichenholz PW. Venous air embolism and cervical microdiscectomy. *Anesth Analg* 1995;81:1287-88.
6. Naulty JS, Miesel LB, Datta S, Ostheimer GW. Air embolism during radical hysterectomy. *Anesthesiology* 1982;57:420-22.
7. Gildenberg PL, O'Brien P, Britt WJ, Frost EAM. The efficacy of Doppler monitoring for detection of venous air embolism. *J Neurosurg* 1981;54:75-78.
8. Palmon SC, Moore LE, Lundberg J, Tuong T. Venous air embolism: A review. *J Clin Anesth* 1997;9:251-57.
9. Furuya H, Suzuki T, Okumura F, Kishi Y, Uefuji T. Detection of air embolism by transesophageal echocardiography. *Anesthesiology* 1983;58:124-29.
10. Chang JL, Albin MS, Bunegin L, Hung TK. Analysis and comparison of venous air embolism detection methods. *Neurosurg* 1980;7:135-41.
11. Matjasko J, Petrozza P, Mackenzie CF. Sensitivity of end-tidal nitrogen in venous air embolism in the dog. *Anesthesiology* 1985;63:418-23.
12. Bedell EA, Berge KH, Losasso TJ. Paradoxical air embolism during venous air embolism: Transesophageal echocardiographic evidence of transpulmonary air passage. *Anesthesiology* 1994;80:947-50.

## ABOUT THE AUTHORS

### Susie J Cho

Resident, Department of Anesthesiology, Thomas Jefferson University Hospital, Philadelphia, Pennsylvania, USA

### Stephen O Bader (Corresponding Author)

Visiting Associate Professor, Department of Anesthesiology University of Pittsburgh, School of Medicine, UPMC Mercy, 1400 Locust Street, Pittsburgh, Pennsylvania 15219, USA, e-mail: baderso@upmc.edu

### James W Heitz

Associate Professor, Department of Anesthesiology and Medicine Jefferson Medical College, Thomas Jefferson University Hospital Philadelphia, Pennsylvania, USA