

CASE REPORT

Role of Transesophageal Echocardiography in Management of Thoracic Stab Wound

¹Navparkash S Sandhu, ²Levon M Capan

ABSTRACT

Transesophageal echocardiography (TEE) is useful in diagnosing cardiac and aortic injuries. A case of stab chest is described in which TEE ruled out cardiac injury, located the knife in the left lung and had potential to change the surgical plan.

Keywords: Echocardiography, Stab chest, Impaled foreign bodies thorax.

How to cite this article: Sandhu NS, Capan LM. Role of Transesophageal Echocardiography in Management of Thoracic Stab Wound. J Perioper Echocardiogr 2014;2(1):32-33.

Source of support: Nil

Conflict of interest: None

INTRODUCTION

Transesophageal echocardiography (TEE) has been used extensively in management of cardiac and aortic injuries.¹⁻³ Although it is difficult to perform prospective studies with penetrating chest injuries, there is ample level 2 evidence suggesting the usefulness of TEE in penetrating cardiac injuries.^{1,2}

CASE REPORT

A 45-year-old black male with history of depression was emergently brought to the ER of trauma center after a suicidal stabbing with a 10 inch long knife blade. The knife handle was *in situ* and was oscillating with cardiac beats. The entry wound was in the left 4th intercostal space just lateral to the sternum (Fig. 1). He was emergently brought to the operating room for removal of the knife and repair of injured structures without any radiologic evaluation. A sternotomy incision was contemplated and the cardiopulmonary bypass team was called in. While the patient was preoxygenated, a 20 G arterial cannula was placed in the left radial artery.

Following a rapid sequence induction using etomidate, 0.2 mg/kg and succinylcholine, 100 mg, direct laryngoscopy, a 7.5 mm internal diameter endotracheal tube was placed into the trachea. Patient remained stable during and after induction.

Following induction, a TEE probe (Hewlett Packard, Bothell, Washington, USA) was introduced into the esophagus. No hemopericardium or cardiac injury was detected. All cardiac valves and septae appeared intact. The knife was in close contact with the left ventricle in dual chamber view. In transgastric view, the knife tip was seen in parenchyma of the left lung (Figs 2A and B).

The surgeon was informed of the findings and a left thoracotomy, instead of sternotomy, was suggested. The surgeon, however, proceeded with sternotomy. On opening the pericardium, no blood was seen in the pericardial cavity. The atria and ventricles appeared normal. There was a small partial thickness cut in the pericardium over the pleural surface. The phrenic nerve was intact. The tip of the knife was seen in the lung and directed toward the spleen. Blood in the pleural cavity was aspirated by the surgeons. There was no injury to the diaphragm. The knife was removed, hemostasis was achieved by cauterizing the pericardial vessels. The lung laceration was repaired using staples. Surgical hemostasis was obtained, and chest tubes were placed bilaterally. The sternotomy incision was closed. Patient was extubated and kept on a suicide watch. His postoperative course was unremarkable.

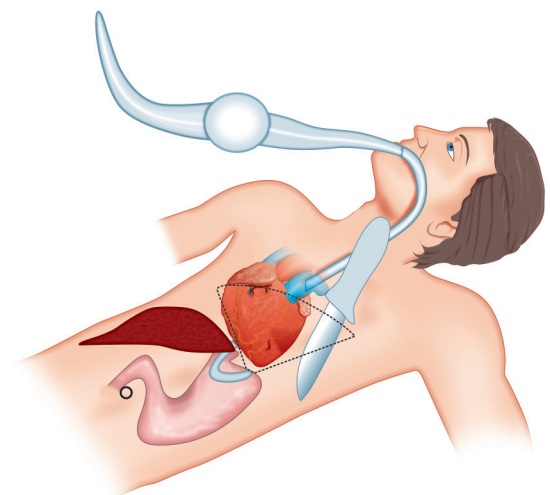
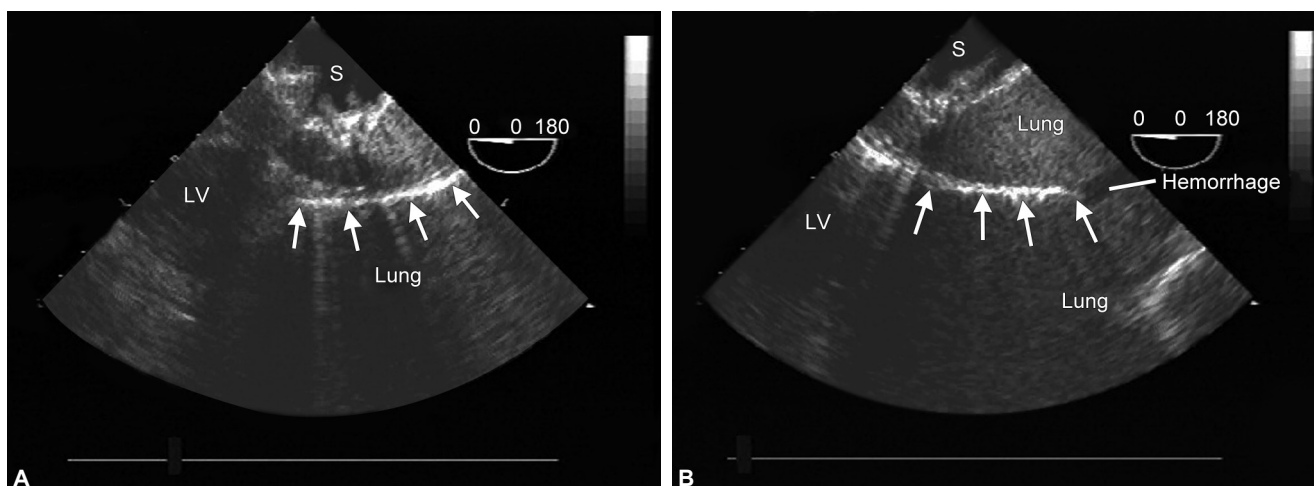


Fig. 1: Diagram depicting position of the knife and TEE probe

¹Clinical Professor, ²Professor and Vice-Chair
¹Department of Anesthesiology, University of California, San Diego, USA
²Department of Anesthesiology, New York University School of Medicine, New York, USA
Corresponding Author: Navparkash S Sandhu, Clinical Professor, Department of Anesthesiology, University of California, 200 West Arbor Drive, San Diego, CA 92103, USA
 e-mail: navparkashsandhu@hotmail.com



Figs 2A and B: Knife blade is seen as a hyperechoic line with shadow marked by arrows (LV: left ventricle, S: stomach)

DISCUSSION

The trajectory of knife and its oscillations with each heartbeat were highly suggestive of cardiac injury. However, TEE examination had successfully ruled out myocardial injury in the absence of pericardial fluid and normal ventricular function. The foreign body was seen in contact with the left ventricle. Additionally, the transgastric view demonstrated the knife blade in the lung. A thoracotomy would have provided a better access to lungs and less risk of osteomyelitis than a sternotomy. Additionally, patient had right-sided chest tubes which cause postoperative pain unlike with left thoracotomy.

Transesophageal echocardiography has proven to be a valuable tool in diagnosing cardiac penetrating injuries. Its usefulness in detecting noncardiac chest injuries is not well established. In this patient, we could visualize the knife adjacent to the left ventricle and in the lung parenchyma with TEE. The role of TEE in detecting foreign body in the myocardium is superior to CT scan⁴ but its usefulness in other thoracic injury is limited. Air in normal lung reflects the ultrasound waves. However, consolidation or collapse of the lung allows ultrasound to penetrate lung and help to imaging of lung in the affected areas. With penetrating

injury, hemorrhage in the lung may lead to obstruction of bronchi leading to partial or total atelectasis. We were able to visualize the lung as hemorrhage in the lung rendered it more sonolucent, making detection of the knife possible. In our case, a transgastric view of TEE was able to image the gastric mucosa and the left lower lobe with the knife in it (Figs 2A and B).

TEE should be used in suspected cardiac injuries and beside providing information about cardiac injury, it may inform the clinician the location of the penetrating foreign bodies such as impaled knives.

REFERENCES

1. Freshman SP, Wisner DH, Weber CJ. 2D echocardiography: emergent use in the evaluation of penetrating precordial trauma. *J Trauma* 1991;31:902-905.
2. Aaland MO, Bryan FC 3rd, Sherman R. Two-dimensional echo in stable victims of penetrating precordial trauma. *Am Surg* 1994;60:412-415.
3. Chiesa R, de Moura MRL, Lucci C, Castellano R, Civilini E, Melissano G, et al. Blunt trauma of the thoracic aorta: mechanism involved, diagnosis and management. *J Vasc Br* 2003;2:197-210.
4. Parasramka SV, Ghotkar S, Kendall J, Fabri BM. Use of transesophageal echocardiography in management of penetrating cardiac injury. *Eur J Echocardiography* 2008;9:563-564.