

CASE REPORT

Role of Transesophageal Echocardiography in Detection of Residual Tumor in Renal Cell Carcinoma Extending into Right Atrium

¹Sunder Lal Negi, ²Vikas Dutta, ³Goverdhan Dutt Puri, ⁴Sethu Madhavan, ⁵Ravi Mohan

ABSTRACT

Renal cell carcinoma (RCC) has a tendency to invade inferior vena cava and thereby reach the right heart. This may necessitate a combined surgical procedure. These procedures impose a challenge to the anesthesiologist and may require the use of veno-venous or cardiopulmonary bypass (CPB). Among the serious and feared complication is embolization of the thrombus during mobilization of the tumor causing a massive pulmonary embolism. Transesophageal echocardiography (TEE) not only provide accurate identification and definition of the cranial extent of the tumor, but may also provide continuous monitoring of the hemodynamic status and cardiac complications during surgical manipulation of tumor. In this case report, we have described TEE helped in recognizing not only the extent of the tumor but also (the adequacy of removal of the tumor thrombus) diagnose the residual tumor after removal during right radical nephrectomy.

Keywords: Transesophageal echocardiography, Renal cell carcinoma, Residual right atrial tumor.

How to cite this article: Negi SL, Dutta V, Puri GD, Madhavan S, Mohan R. Role of Transesophageal Echocardiography in Detection of Residual Thrombus in Renal Cell Carcinoma extending into Right Atrium. *J Perioper Echocardiogr* 2015;3(1):35-38.

Source of support: Nil

Conflict of interest: None

INTRODUCTION

Renal cell carcinoma (RCC) is a common urological tumor, representing 1 to 3% of all visceral cancers and 85 to 90% of all malignant kidney tumors. The extension of tumor thrombus into the inferior vena cava (IVC) in RCC is 4 to

25% of all cases.¹ Renal cell carcinoma has the tendency to infiltrate into the renal vein and then into the inferior vena cava. Approximately, 2 to 10% of these patients have tumor thrombus extending into the RA which may requires excision under cardiopulmonary bypass (CPB).

Five years survival rate of thrombus extending into IVC and right atrium is 25 to 75%.²

Major causes of perioperative mortality in such cases are pulmonary embolism, myocardial infarction and complications of CPB.³ However, with better perioperative management and standardization of the surgical and vascular bypass techniques, the mortality rate has decreased considerably. Introduction of dynamic monitoring by transesophageal echocardiography and the adoption of bypass techniques including CPB and hypothermic circulatory arrest (HCA) have improved the safety and completeness of these challenging procedures.

CASE REPORT

A 64-year-old female weighing 56 kg presented with continuous low grade fever following bilateral total knee replacement 20 days back. Her hemoglobin was 9.7 gm% and kidney function tests were within normal limits. Ultrasonography scan showed a mass in the right kidney involving middle and lower pole extending to the renal vein and inferior vena cava. Contrast-enhanced computed tomography showed a heterogenous mass of 8.6 × 6.6 cm involving the middle and lower pole of right kidney (Fig. 1) and was extending into right renal vein and infrahepatic part of IVC.

Echocardiography showed IVC filled with tumor extending into right atrium. Preanesthetic assessment showed healthy patient with arterial pressure (BP) of 150/90 mm Hg and heart rate of 100 beats per minute. Right open radical nephrectomy with removal of IVC and right atrial thrombus was planned by surgeon with standby CPB. Patient was induced with Fentanyl and propofol titrated to BIS of 50 and Vecuronium. Surgical technique presence and extension of tumor in the RA was confirmed (Fig. 2, Video 1). Central venous cannulation was performed using right IJV ensuring the guide wire do not go into right atrium under TEE guided and secured the catheter at 12 cm mark.

^{1,2}Senior Resident, ³Professor, ^{4,5}Assistant Professor

¹⁻⁴Department of Anesthesia and Intensive Care, Advanced Cardiac Center, Postgraduate Institute of Medical Education and Research, Chandigarh, India

⁵Department of Urology, Advanced Urology Center Postgraduate Institute of Medical Education and Research Chandigarh, India

Corresponding Author: Sunder Lal Negi, Senior Resident Department of Anesthesia and Intensive Care, Advanced Cardiac Center, Postgraduate Institute of Medical Education and Research, Chandigarh, 160012, India, Phone: 91+9888446388, e-mail: dr.sundernegi@gmail.com

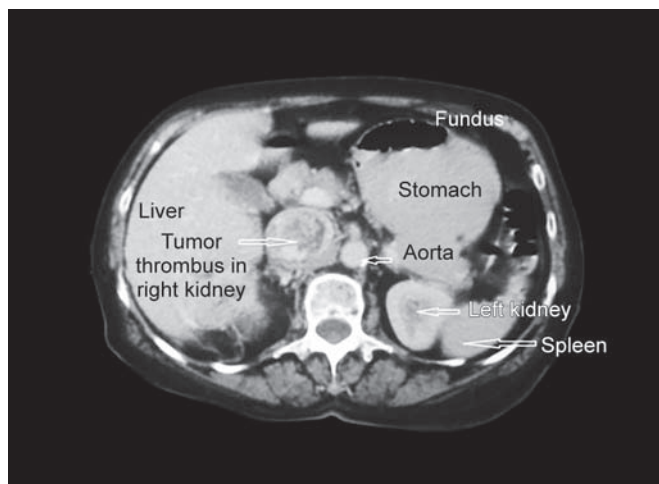


Fig. 1: Contrast-enhanced computed tomography showing heterogenous mass in middle and lower lobe of right kidney

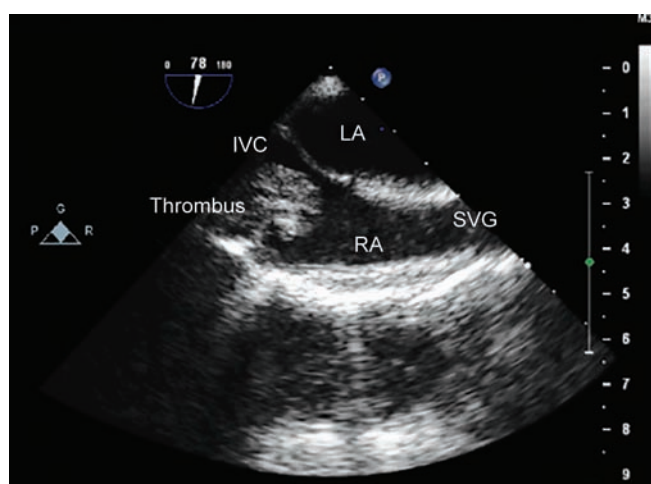


Fig. 2: Transesophageal echocardiography visualization of intraatrial tumor thrombus in bicaval view

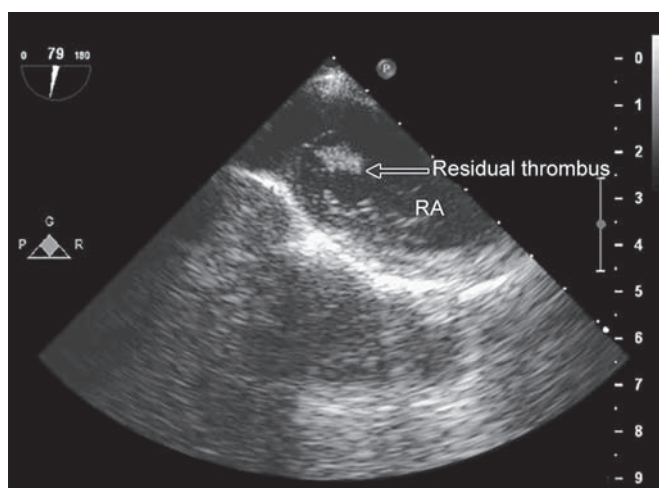


Fig. 3: Transesophageal echocardiography showing residual tumor attached to pectinate muscle in right atrium

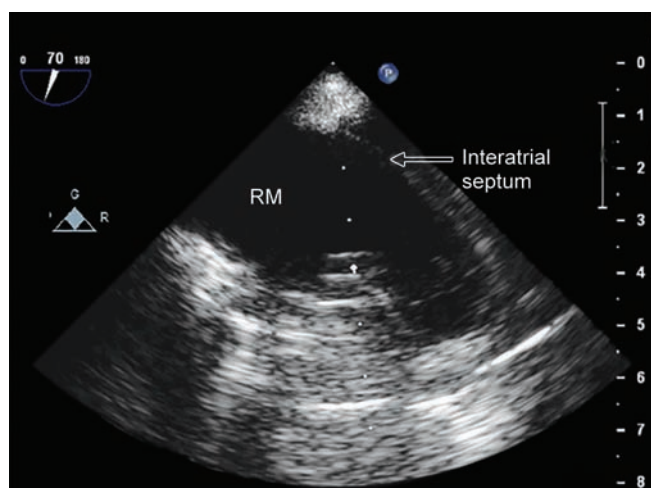


Fig. 4: No residual thrombus is seen in right atrium on transesophageal echocardiography after retrieval of thrombus on cardiopulmonary bypass

Anesthesia was maintained with air, oxygen, propofol and fentanyl. Midline abdominal incision was given extending from xiphoid to 5 cm below umbilicus. Tumor was involving whole kidney and was around 20 × 10 cm. Initially, infrarenal IVC was dissected out and looped followed by right renal vein dissection. Transesophageal echocardiography monitoring to detect potential emboli was continued throughout the operation by TEE. Right renal artery was also dissected out at its origin and was ligated. Next right ureter and gonadal vein were dissected out inferiorly and ligated and divided.

Right kidney was freed circumferentially by cautery dissection and IVC was looped at infrahepatic level. During this period of IVC clamping, patient developed severe hypotension for around 7 minutes and was managed with fluid 500 ml crystalloid and TEE monitoring was continued to rule out the pulmonary thromboembolism as cause of hypotension. The infra-hepatic control was tightened to decrease the bleed while venacavotomy was repaired. Once the tumor was removed from IVC, TEE

showed a presence of residual tumor in right atrium (RA) which was attached to pectinate muscle (Fig. 3, Video 2). Subsequent to this finding the plan to remove the rest of the tumor under CPB was made. Following sternotomy, 4 mg/kg body weight of heparin was given to achieve ACT of > 480 seconds and aortic, superior vena cava cannulation were performed while sucker was put in IVC. Patient was put on partial CPB and residual tumor was removed via right atriotomy followed by RA closure. Total CPB time was 14 minutes. The patient was weaned off from CPB in sinus rhythm with stable hemodynamics. Transesophageal echocardiography showed no residual atrial tumor (Fig. 4, Video 3). Post surgery patient was extubated and postoperative course was uneventful.

DISCUSSION

Intravascular tumor growth along the renal vein into the IVC and to the RA occurs in up to 15 and 1% of RCC patients respectively. The RCC caval thrombi can be

classified as group I: Venous thrombus in the renal vein not reaching IVC, group II: Infrahepatic IVC thrombus, group III: Thrombi in retrohepatic or suprahepatic IVC not reaching the RA, group IV: RA Thrombi.⁴

Renal cell carcinoma with cavoatrial involvement by tumor thrombi may present unique challenges in anesthetic management. The most notable among these are deranged kidney function with or without renal arteriovenous malformation, pathological fractures from bony metastasis, anemia secondary to decreased erythropoietin, hypertension from secretion of renin by the tumor cells, hypercalcemia and paraneoplastic disease.⁵

Complete obstruction of IVC, though not a common presentation, can manifest with clinical features, like recurrent pulmonary emboli, pedal edema, renal or hepatic dysfunction, malabsorption and engorgement of abdominal veins. These patients can tolerate clamping of IVC without significant hemodynamic compromise.⁶ In patients with poor collateral development, IVC cross clamping can lead to central hypovolemic shock. In RCC with thrombus extending in to right atrium, guide wires and central venous catheters should not be advanced too far into right atrium and ideally should be placed under ultrasound or TEE guidance. In view of the danger of tumor dislodgement and embolization, pulmonary artery catheterization should be avoided in favor of other safer modes of monitoring, e.g. TEE, Esophageal Doppler probes. Moreover, IVC obstruction leads to dilation of epidural veins and caution should be exercised if epidural catheterization is attempted.

Statistically, less than 0.4% of all RCCs and less than 5% of those involving the IVC embolize during surgery.⁷ Perioperative mortality rates have been reported between 2.7 and 13% for IVC extension of RCC.⁸ There is a high risk of pulmonary embolism leading to sudden death during surgical manipulation.⁹ Introduction of TEE helps during removal of thrombus, detection of residual thrombus and detection of embolism. The adoption of bypass including CPB and HCA has improved the safety and completeness of these challenging procedures.¹⁰

The infrahepatic extension of these tumors is best managed by a standard radical nephrectomy with tumor thrombectomy.¹ These level 2 or 3 tumor extensions can be managed without any form of bypass by achieving control of intrapericardial IVC through thoracoabdominal approach. These tumors can also be removed by isolating and clamping suprahepatic IVC through an abdominal approach.¹¹ This procedure entails considerable dissection and manipulation of IVC, thereby increasing the risk of preoperative embolization.

The criticism of the technique involving IVC clamping includes bleeding from hepatic and lumbar veins, or from poor control of the major vascular structures and occasional hemodynamic instability that precludes total resection of the tumor.^{11,12} It is generally agreed that when tumor thrombus extends into the RA, CPB with or without HCA is essential for safe and complete extraction of the thrombus.^{11,13} Avoiding circulatory arrest to remove these tumors does have an advantage of shorter bypass time and reduced risk of bleeding. However, there is reduced visualization and exposure, because of presence of blood in the operative field and hepatic congestion.

CONCLUSION

A good understanding of the anesthetic implications in RCC is of paramount importance in its successful management. This case also reinforces the routine intraoperative use of TEE which not only helps in defining the extent of tumor into the IVC and RA but also helps in detecting any residual tumor after excision and also confirms re-establishment of IVC and hepatic venous blood flow. We also wish to state that DHCA is not necessary in all cases of RCC requiring CPB and risk benefit ratio needs to be individualized. It can also help in detecting any embolization during the mobilization process of a renal cell carcinoma, by constantly monitoring the right ventricular functions and embolism pathway. Though RCC with RA extension can be managed without CPB but if catastrophe occurs then one can lose precious time in going on CPB and then it may also be difficult to remove the embolism if it goes too distally.

REFERENCES

1. Nesbitt JC, Soltero ER, Dinney CP, Walsh GL, Schrupp DS, Swanson DA, Pisters LL, Willis KD, Putnam JB Jr. Surgical management of renal cell carcinoma with inferior vena cava tumor thrombus. *Ann Thorac Surg* 1997;63(6):1592-1600.
2. Gonzalez-Fajardo JA, Fernandez E, Rivera J, Pelaz A, Gonzalez-Zarate J, Alvarez JC, Gonzalez E, Vaquero C. Transabdominal surgical approach in the management of renal tumors involving the retrohepatic inferior vena cava. *Ann Vasc Surg* 2000;14(5):436-443.
3. Blute ML, Leibovich BC, Lohse CM, Cheville JC, Zincke H. The Mayo Clinic experience with surgical management, complications and outcome for patients with renal cell carcinoma and venous tumour thrombus. *BJU Int* 2004;94(1):33-41.
4. Ciancio G, Vaidya A, Savoie M, Soloway M. Management of renal cell carcinoma with level III thrombus in the IVC. *J Urol* 2002;168(4):1374-1377.
5. Pepper K, Jaowattana U, Starsiak MD, Halkar R, Hornaman K, Wang W, Dayamani P, Tangpricha V. Renal cell carcinoma presenting with paraneoplastic hypercalcemic coma: a case report and review of the literature. *J Gen Intern Med* 2007;22(7):1042-1046.

6. Kaplan S, Ekici S, Dogan R, Demircin M, Ozen H, Pasaoglu I. Surgical management of renal cell carcinoma with inferior vena cava tumor thrombus. *Am J Surg* 2002;183(3):292-299.
7. Neves RJ, Zinke H. Surgical treatment of renal cancer with vena cava extension. *Br J Urol* 1987;59(5):390-395.
8. Terakawa T, Miyake H, Takenaka A, Hara I, Fujisawa M. Clinical outcome of surgical management for patients with renal cell carcinoma involving the inferior vena cava. *Int J Urol* 2007;14(9):781-784.
9. Kumamoto T, Nishi M. Anesthetic management of a patient with renal cell carcinoma extending into the right atrium. *Masui* 2010 Apr;59(4):514-518.
10. Stewart JR, Carey JA, McDougal WS, Merrill WH, Koch MO, Bender HW. Cavoatrial tumor thrombectomy using cardio-pulmonary bypass without circulatory arrest. *Ann Thorac Surg* 1991;51(5):717-721.
11. Swierzewski DJ, Swierzewski MJ, Libertino JA. Radical nephrectomy in patients with renal cell carcinoma with venous, vena caval, and atrial extension. *Am J Surg* 1994;168(2):205-209.
12. Skinner DG, Pritchett TR, Lieskovsky G, Boyd SD, Stiles QR. Vena caval involvement by renal cell carcinoma. Surgical resection provides meaningful long-term survival. *Ann Surg* 1989;210(3):387-392.
13. Belis JA, Levinson ME, Pae WE Jr. Complete radical nephrectomy and vena caval thrombectomy during circulatory arrest. *J Urol* 2000;163(2):434-436.