

# Transesophageal Echocardiographic Assessment of Hemodynamic Changes during Laparoscopic Surgeries at High Altitude

Krishna P Gourav<sup>1</sup>, Goverdhan Dutt Puri<sup>2</sup>, Tsering Morup<sup>3</sup>, Sunder L Negi<sup>4</sup>

## ABSTRACT

**Introduction:** Anesthesia at high altitudes is challenging due to vast variations in physiology, which are further complicated by the positioning and pneumoperitoneum during laparoscopic surgeries. These changes can be better understood and managed with the help of echocardiography. Here, we demonstrate the effect of laparoscopy on hemodynamics with the help of transesophageal echocardiography (TEE) at high altitudes in three patients.

**Materials and methods:** Three ASA I patients (patient 1, laparoscopic cholecystectomy; patient 2, laparoscopic vaginal hysterectomy; patient 3, laparoscopic hernioplasty with mesh repair) who underwent laparoscopic surgeries at an altitude of 3,500 m were studied. Various parameters were measured by TEE which included left ventricle ejection fraction (EF), left ventricular outflow tract (LVOT) velocity time integral (VTI), cardiac output (CO), E/A, E/e<sup>1</sup>, tricuspid annular plane systolic excursion (TAPSE), and pulmonary artery acceleration time (PAAT). The mean arterial pressure (MAP), heart rate, SpO<sub>2</sub>, and end-tidal carbon dioxide were also measured. These parameters were recorded at 10-time points: before induction of anesthesia (T1), before insufflation (T2), after positioning (T3), 5 mm Hg pneumoperitoneum (T4), 10 mm Hg pneumoperitoneum (T5), 14 mm Hg pneumoperitoneum (T6), 10 minutes after 14 mm Hg pneumoperitoneum (T7), 20 minutes after 14 mm Hg pneumoperitoneum (T8), 30 minutes after 14 mm Hg pneumoperitoneum (T9), and 5 minutes after desufflation (T10).

**Results:** We observed a decrease in MAP, LVOT VTI, and CO after pneumoperitoneum when associated with reverse RT position and an increase in MAP, LVOT VTI, and CO when associated with Trendelenburg position. The right ventricular systolic function measured by TAPSE, left ventricular EF, and LV diastolic function remained the same throughout the procedure in all the three patients. Pulmonary artery acceleration time gradually decreased after pneumoperitoneum in all the three patients but stayed in a normal range throughout the procedure. The results of our study are consistent with the previous studies performed at sea level.

**Conclusion:** The present study showed that laparoscopic surgeries may be safely performed in healthy individuals at high altitudes. However, the study was limited by small sample size and done only in healthy subjects.

**Keywords:** High altitude, Laparoscopic surgeries, Transesophageal echocardiography.

*Journal of Perioperative Echocardiography* (2019): 10.5005/jp-journals-10034-1106

## INTRODUCTION

Laparoscopic surgeries are rapidly evolving due to less postoperative pain, less fatigue, better cosmesis, early return of normal activities, shorter hospital stays, and disability from work as compared to open surgeries.<sup>1</sup> However, these surgeries are associated with various hemodynamic changes during various phases of laparoscopic surgeries. These changes can be attributed due to anesthesia, positioning, pneumoperitoneum, hypercarbia, or desufflation.<sup>2</sup> Anesthesia at high altitudes is a challenging job due to vast variations in physiology, which can further be complicated by the positioning and pneumoperitoneum during laparoscopic surgeries. These changes can be better understood and managed with the help of echocardiography. In recent years, due to the development of surgical expertise and a better understanding of the pathophysiology of pneumoperitoneum, it becomes possible to offer laparoscopic surgeries to patients having comorbidities with minimal morbidity and mortality.<sup>3</sup> However, knowledge of hemodynamic changes in laparoscopic surgeries done at high altitudes is limited. We are hereby, sharing our experience of the effect of laparoscopy on hemodynamics with the help of transesophageal echocardiography (TEE) at high altitudes in three patients. Written informed consent was obtained from all three patients.

<sup>1,2</sup>Department of Cardiac Anaesthesia, Postgraduate Institute of Medical Education and Research, Chandigarh, India

<sup>3</sup>Department of Anesthesia, Sonam Norboo Hospital, Old Leh Rd, Leh-Ladakh, Ladakh, India

<sup>4</sup>Department of Anesthesia and Intensive Care, Postgraduate Institute of Medical Education and Research, Chandigarh, India

**Corresponding Author:** Sunder L Negi, Department of Anesthesia and Intensive Care, Postgraduate Institute of Medical Education and Research, Chandigarh, India, Phone: +91 9888446388, e-mail: dr.sundernegi@gmail.com

**How to cite this article:** Gourav KP, Puri GD, Morup T, *et al.* Transesophageal Echocardiographic Assessment of Hemodynamic Changes during Laparoscopic Surgeries at High Altitude. *J Perioper Echocardiogr* 2019;7(2):44–47.

**Source of support:** Nil

**Conflict of interest:** None

## MATERIALS AND METHODS

Three American Society of Anaesthesiologists (ASA) 1 patient (residents of Leh; India), who underwent laparoscopic surgery at Sonam Norboo hospital (Leh-Ladakh; India) at an altitude of 3,500 m were included in the study. The surgeries were

performed under general anesthesia with continuous monitoring of the electrocardiogram, pulse oximeter, invasive systemic blood pressure, and capnography. Anesthesia was induced with fentanyl 2 µg/kg, propofol 1–2 mg/kg, and vecuronium 0.1 mg/kg after pre-oxygenation with 100% oxygen for 3 minutes, followed by orotracheal intubation. Maintenance of anesthesia was performed with isoflurane (minimum alveolar concentration—1) and with intermittent doses of vecuronium. The patients were ventilated using volume-controlled ventilation mode, with a tidal volume of 8 mL/kg, positive end-expiratory pressure of 5 cmH<sub>2</sub>O, and the respiratory rate was adjusted to maintain an end-tidal carbon dioxide of 35 mm Hg. A TEE probe (x7-2t; EpiqCVx; Philips; USA) was inserted into the esophagus after deflating the stomach contents. The pneumoperitoneum was instituted and maintained by a continuous insufflation of carbon dioxide (CO<sub>2</sub>) by the 11 mm trocar. Various parameters were measured by echocardiography which included left ventricle ejection fraction (EF) (measured in mid-esophageal 4 chamber view), left ventricular outflow tract (LVOT) velocity time integral (VTI) (measured in transgastric long-axis view), cardiac output (CO), E/A, E/e<sup>l</sup> (measured in mid-esophageal 4 chamber view), tricuspid annular plane systolic excursion (TAPSE), and pulmonary artery acceleration time (PAAT) (measured in transgastric basal RV view). The baseline echo parameters before induction of anesthesia were done with X5-1 (EpiqCVx; Philips; USA) transthoracic echocardiography probe. Transesophageal echocardiography was done by an experienced echocardiographer who has done more than 100 examinations. The mean arterial pressure (MAP), heart rate (HR), oxygen saturation (SpO<sub>2</sub>), and ETCO<sub>2</sub> were also noted. These parameters were recorded at 10-time points: before induction of anesthesia (T1), after induction (before insufflation) (T2), after positioning (T3), at 5 mm Hg pneumoperitoneum (T4), 10 mm Hg pneumoperitoneum (T5), 14 mm Hg pneumoperitoneum (T6), 10 minutes after 14 mm Hg pneumoperitoneum (T7), 20 minutes after 14 mm Hg pneumoperitoneum (T8), 30 minutes after 14 mm Hg pneumoperitoneum (T9), and 5 minutes after desufflation (T10).

## RESULTS

Table 1 shows baseline demographics and surgical details. The MAP decreased in patient 1 after the reverse Trendelenburg (RT) position and pneumoperitoneum and increased after administration of 500 mL normal saline (NS). Whereas in patients 2 and 3, the MAP increased after instituting Trendelenburg position and gradually decreased after the institution of pneumoperitoneum (Table 2). On echocardiography examination, the right ventricular systolic function, as measured by TAPSE, the left ventricle (LV) EF and LV

diastolic function remained the same throughout the procedure in all the three patients (Figs 1 to 3 and Table 3). The LVOT VTI and CO decreased in patient 1 after the RT position and pneumoperitoneum which normalized after administration of 500 mL NS (Fig. 1). Whereas in patients 2 and 3, the LVOT VTI and CO abruptly increased after instituting Trendelenburg position and gradually normalized after the institution of pneumoperitoneum (Figs 2 and 3). The PAAT gradually decreased after pneumoperitoneum but stayed in a normal range in all the three patients throughout the procedure (Figs 1 to 3).

## DISCUSSION

In the present observational study, we found a decrease in MAP, LVOT VTI, and CO after pneumoperitoneum when associated with reverse RT position and an increase in MAP, LVOT VTI, and CO when associated with Trendelenburg position. The right ventricular systolic function, as measured by TAPSE, the left ventricular EF and LV diastolic function (filling pressures) remained the same throughout the procedure in all the three patients. Pulmonary artery acceleration time gradually decreased after pneumoperitoneum in all the three patients but stayed in a normal range throughout the procedure. The results of our study are consistent with previous studies performed at sea level.

A slow decline in pulmonary hypertension (PH) after birth was observed in highlanders when compared to lowlanders due to delayed remodeling of the distal pulmonary vasculature. The increased amount of smooth muscle cells in the distal pulmonary arteries and arterioles are considered the primary reason for PH in healthy highlanders. Vasoconstriction, hypervolemia, polycythemia, and increased blood viscosity due to hypoxia play as secondary factors for the development of PH in highlanders. All these findings become exaggerated when healthy highlanders lose their ability for adaptation and can develop congestive heart failure.

Laparoscopic surgeries are associated with four potential major physiological changes in the anesthetized patients which include Trendelenburg/RT (reverse Trendelenburg) position, creation of pneumoperitoneum, systemic absorption of carbon dioxide (CO<sub>2</sub>), and desufflation of pneumoperitoneum.<sup>2</sup> Laparoscopic procedures involving the lower abdomen are done in 10–20° Trendelenburg position to keep the small bowel and colon out of the pelvis and to decrease complications associated with blind trocar insertion, whereas laparoscopic procedures involving the upper abdomen are performed in 10–20° reverse Trendelenburg position. The cardiovascular changes may be influenced by the patient's age, the extent of tilt, intravascular volume status, anesthetic drugs, ventilation techniques, and associated cardiac disease in Trendelenburg/RT position.<sup>4</sup> Dorsay et al. concluded that pneumoperitoneum alone has minimal hemodynamic effects and saw an 11% decrease in the cardiac index after the addition of RT position.<sup>5</sup> Joris et al. found a 50% decrease in the cardiac index in healthy young patients with the combined effects of anesthesia, RT position, and pneumoperitoneum.<sup>6</sup> To counteract these effects, measures such as volume loading or Trendelenburg position can help in preventing a decrease in SV. In our patients, the adoption of the Trendelenburg position in patients 2 and 3 was not associated with significant cardiovascular changes, whereas, RT positioning in patient 1 was associated with a decrease in MAP, LVOT VTI, and CO, probably due to the gravitational effect on venous return.<sup>7</sup>

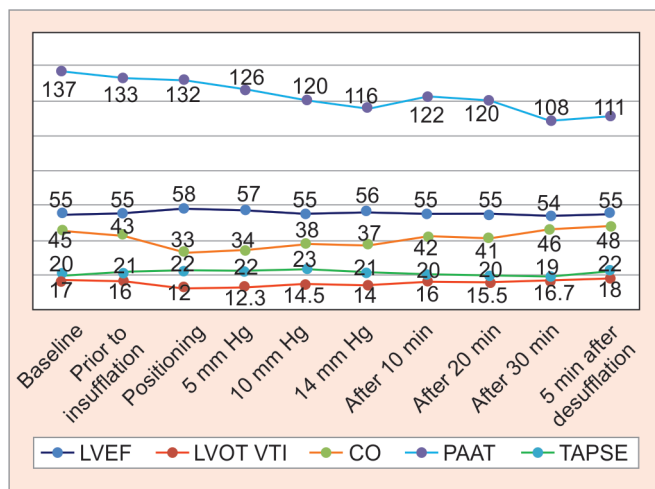
**Table 1:** Demographics and surgical details

	Patient 1	Patient 2	Patient 3
Age	29	42	60
Gender	F	M	M
Diagnosis	Gall bladder stone	Uterine fibroid	Indirect inguinal hernia
Surgery done	Laparoscopic cholecystectomy	Laparoscopic vaginal hysterectomy	Laparoscopic hernioplasty with mesh repair
Position	Reverse Trendelenburg	Trendelenburg	Trendelenburg

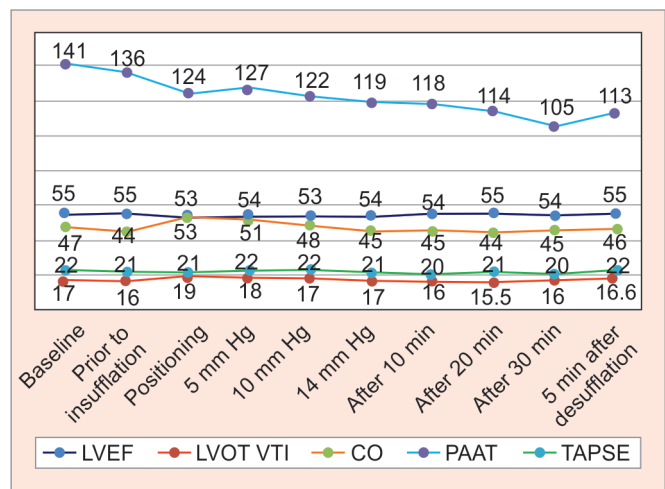
**Table 2:** Hemodynamic data of the three patients

	Patient 1			Patient 2			Patient 3		
	H/R	MAP	ETCO <sub>2</sub>	H/R	MAP	ETCO <sub>2</sub>	H/R	MAP	ETCO <sub>2</sub>
Baseline	76	85		73	86		69	96	
After induction (prior to insufflation)	79	78	34	75	75	33	68	98	32
Positioning	84	65	36	70	108	37	62	101	36
5 mm Hg	84	68	35	73	101	34	64	98	33
10 mm Hg	86	66	35	67	99	35	68	97	34
14 mm Hg	88	63	36	75	96	37	64	96	36
After 10 minutes	79	74	36	73	90	36	69	96	36
After 20 minutes	76	80	37	73	85	37	70	95	35
After 30 minutes	79	86	37	70	82	36	71	92	37
5 minutes after desufflation	80	79	36	68	81	36	70	86	36

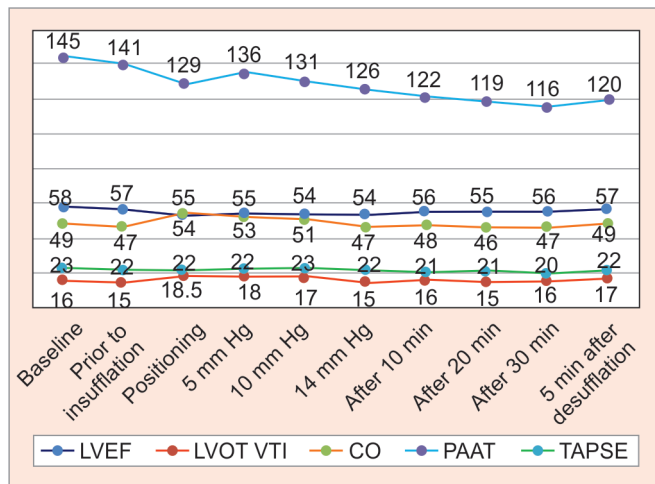
H/R, heart rate; MAP, mean arterial pressure; ETCO<sub>2</sub>, end-tidal carbon dioxide



**Fig. 1:** Echocardiographic parameters measured at different time points in laparoscopic cholecystectomy



**Fig. 2:** Echocardiographic parameters measured at different time points in laparoscopic vaginal hysterectomy



**Fig. 3:** Echocardiographic parameters measured at different time points in laparoscopic hernioplasty with mesh repair

The cardiovascular changes associated with pneumoperitoneum will depend upon the patient characteristics, intravascular volume, intra-abdominal pressure attained, rate of insufflation, the volume

of CO<sub>2</sub> absorbed, anesthetic agents, and ventilatory technique employed. During pneumoperitoneum, inferior vena cava (IVC) flow decreases due to an increase in intraperitoneal pressure as the IVC segment between the liver and the diaphragm significantly narrows representing the primary impact on SV during laparoscopic procedures. Pneumoperitoneum created by CO<sub>2</sub> produces an array of physiological reactions that are distinctive to laparoscopic surgery and can cause deleterious effects to a minority of patients. When blood concentrations are elevated, CO<sub>2</sub> has significant cardiovascular effects which include myocardial depression, vasodilatation, and tachycardia. A mean decrease in CO by 17% was noted by Lenz et al. after insufflation of 4 to 5 L of CO<sub>2</sub> while in the Trendelenburg position.<sup>8</sup> Similarly, Joris et al. noticed a 30–40% reduction in CI after CO<sub>2</sub> insufflation.<sup>6</sup> However, a study done by Joshi et al. saw a preserved cardiac index measured by TEE Doppler at intra-abdominal pressure of 12–15 mm Hg.<sup>9</sup> In healthy individuals, cardiovascular alterations due to pneumoperitoneum and CO<sub>2</sub> absorption are well tolerated.<sup>5</sup> However, its effect on healthy individuals living at high altitudes is not yet studied much. The cardiovascular parameters in patients 2 and 3 were stable even after pneumoperitoneum in the current study which may be due to the adoption of the Trendelenburg position. Whereas in patient 1, there is a decrease in MAP, LVOT VTI, and CO at time point 2, 3,

**Table 3:** Echocardiographic data of diastolic dysfunction at a different time period of the study

	Patient 1		Patient 2		Patient 3	
	E/A	E/e' <sup>l</sup>	E/A	E/e' <sup>l</sup>	E/A	E/e' <sup>l</sup>
Baseline	<b>1.4</b>	<b>9</b>	<b>1.2</b>	<b>8</b>	<b>1.3</b>	<b>7</b>
After induction	1.3	9	1.2	8	1.3	6
Positioning	1.3	10	1.1	8.5	1.3	6
5 mm Hg	1.4	10	1.2	8	1.3	7
10 mm Hg	1.3	9.5	1.2	8	1.2	7
14 mm Hg	1.3	9.5	1.2	8	1.1	6
After 10 minutes	1.2	10	1.3	8.5	1.2	5.5
After 20 minutes	1.2	9.5	1.3	8	1.1	6
After 30 minutes	1.3	9	1.2	8	1.3	6.5
5 minutes after desufflation	1.3	9.5	1.2	8	1.3	7

4, and 5 which may be attributed to RT position which was further aggravated by the pneumoperitoneum. However, hemodynamics became stable after the administration of intravenous fluid. The LVEF in our study remained stable throughout the procedure in all the three patients. These results are consistent with the observations of Cunningham et al. and D'Ugo et al. as determined by TEE.<sup>4,10</sup> In contrast to these studies, Ramos et al. showed a significant decrease in LVEF after pneumoperitoneum in relation to the period before CO<sub>2</sub> insufflation.<sup>11</sup> However, they included the older population and saw only a minimal fall in LVEF, i.e., 5.24%. The PAAT which is a surrogate marker of pulmonary arterial hypertension gradually decreased after the installation of pneumoperitoneum in all three cases which may be attributed to CO<sub>2</sub> absorption or due to increase peak airway pressures which increase the pulmonary vascular resistance.<sup>12</sup> However, it was always maintained in a normal range.

In summary, the present study showed that laparoscopic surgeries may be safely performed in healthy individuals at high altitudes. However, the study was limited by small sample size and done only in healthy subjects. Hence, studies with a large sample size with various comorbidities at high altitudes are warranted.

**REFERENCES**

1. Rubert CP, Farias FV, Higa RA. Comparison between open and laparoscopic elective cholecystectomy in elderly, in a teaching hospital. *Rev Col Bras Cir* 2016;43(1):2–5. DOI: 10.1590/0100-69912016001002.
2. Atkinson TM, Giraud GD, Togioka BM, et al. Cardiovascular and ventilatory consequences of laparoscopic surgery. *Circulation* 2017;135(7):700–710. DOI: 10.1161/CIRCULATIONAHA.116.023262.
3. Airan M, Appel M, Berci G, et al. Retrospective and prospective multi-institutional laparoscopic cholecystectomy study organized

by the society of american gastrointestinal endoscopic surgeons. *Surg Endosc* 1992;6(4):169–176. DOI: 10.1007/BF02210874.

4. Cunningham AJ, Turner J, Rosenbaum S, et al. Transoesophageal echocardiographic assessment of haemodynamic function during laparoscopic cholecystectomy. *Br J Anaesth* 1993;70(6):621–625. DOI: 10.1093/bja/70.6.621.
5. Dorsay DA, Greene FL, Baysinger CL. Hemodynamic changes during laparoscopic cholecystectomy monitored with transesophageal echocardiography. *Surg Endosc* 1995;9(2):128–133. ; discussion 133–4.
6. Joris JL, Noirot DP, Legrand MJ, et al. Hemodynamic changes during laparoscopic cholecystectomy. *Anesth Analg* 1993;76(5):1067–1071. DOI: 10.1213/00000539-199305000-00027.
7. Schiller WR. The trendelenburg position. Surgical requirements. In: Martin JT, ed. *Positioning in anesthesia and surgical requirements*. Philadelphia: W.B. Saunders; 1987. pp. 112–126.
8. Lenz RJ, Thomas T, Wilkins G. Cardiovascular changes during laparoscopy: studies of stroke volume and cardiac output using impedance cardiography. *Anaesthesia* 1976;31(1):4–12. DOI: 10.1111/j.1365-2044.1976.tb11738.x.
9. Joshi GP, Hein HT, Mascarenhas WL, et al. Continuous transesophageal echo-Doppler assessment of hemodynamic function during laparoscopic cholecystectomy. *J Clin Anesth* 2005;17(2):117–121. DOI: 10.1016/j.jclinane.2004.06.007.
10. D'Ugo D, Persiani R, Pennestri F, et al. Transesophageal echocardiographic assessment of hemodynamic function during laparoscopic cholecystectomy in healthy patients. *Surg Endosc* 2000;14(2):120–122. DOI: 10.1007/s004649900080.
11. Ramos LP, Araújo RB, Castro M, et al. Hemodynamic evaluation of elderly patients during laparoscopic cholecystectomy. *Revista do Colégio Brasileiro de Cirurgiões* 2018;45(2):e1659. DOI: 10.1590/0100-6991e-20181659.
12. Murthy TV, Gupta P. Laparoscopic cholecystectomy with pulmonary hypertension: anaesthetic challenges-a case report. *Indian J Anaesth* 2008;52(2):217.